
Molecular Diagnosis of Dysmorphic Syndromes and Inherited Metabolic Disorders in Thailand

VORASUK SHOTELERSUK, MD*

Abstract

While dysmorphic syndromes and inherited metabolic disorders are individually rare, they collectively account for a significant proportion of illnesses, especially in children. They present clinically in a wide variety of ways, involving virtually any organ or tissue of the body making them relatively difficult to diagnose. However, reaching an accurate diagnosis for children with dysmorphic features and suspected inherited metabolic disorders is important to them and their families both for treatment and for the prevention of disease in other family members. It also makes all the accumulated knowledge available about the relevant condition.

Molecular techniques have kindled a revolution in the diagnosis of genetic disorders, including dysmorphic syndromes and inherited metabolic disorders. Molecular methods essentially avoid problems of other techniques. This review exemplifies some of the diseases that can be diagnosed by molecular tools available in Thailand and illustrates some of their benefits.

Key word : Molecular Diagnosis, Dysmorphic Syndromes, Inherited Metabolic Disorders

SHOTELERSUK V

J Med Assoc Thai 2003; 86 (Suppl 2): S129-S134

Dysmorphic syndromes and inherited metabolic disorders are two groups of human diseases that have long been relatively difficult to diagnose and treat, making them bitter pills for many physicians.

Recent advances in molecular techniques in association with the Human Genome Project (HGP) have led to the identification of several human disease genes. One of its benefits would be for diagnosis of these

* Department of Pediatrics, Faculty of Medicine, Chulalongkorn University, Bangkok 10330, Thailand.

diseases. This article exemplifies some of the diseases that can be diagnosed by molecular tools available in Thailand and illustrates some of their benefits.

Molecular diagnosis

Molecular techniques have kindled a revolution in the diagnosis of genetic disorders. In the past, genetic diagnosis was based solely on clinical features, cytogenetic methods, or biochemical tests. Clinical criteria, however, can be indistinct. In addition, some findings may develop later in life, resulting in long periods of ambiguity in the diagnosis. Cytogenetic tests can be used to diagnose only diseases with chromosomal abnormalities, which are not the majority of genetic diseases. Biochemical tests can produce ambiguous results and usually require expensive and invasive studies. Moreover, clinical criteria and biochemical tests have important limitations when used to identify carriers or make a prenatal diagnosis.

Molecular methods essentially avoid these problems. Such methods can unequivocally determine the presence or absence of a gene mutation in a patient or carrier. Because one's genetic material virtually does not change during lifetime, a molecular diagnosis can be made far in advance of the development of clinical symptoms. It requires only a sample of DNA, which is present in any nucleated cells, such as peripheral blood leukocytes. Therefore, there is no need for invasive procedures, for instance a biopsy of affected tissues. Prenatal diagnosis can possibly be made by obtaining chorionic villus or amniotic-fluid cells. Moreover, due to the high specificity of molecular diagnostic testing, screening populations for carriers is possible for some diseases.

Theoretically, molecular diagnosis of any disease whose responsible genes have been identified can be made in Thailand. But practically, due to the heterogeneity and the nature of genetic changes that underlie the disorders, molecular testing for different diseases has different levels of difficulty. Therefore, for disorders that are relatively homogeneous at the molecular level, molecular tests can be performed rapidly (within one day) and inexpensively (could cost in the same range as an echocardiogram or a skeletal survey). But for diseases whose molecular defects are extremely heterogeneous, their molecular testing can be a daunting task. Nonetheless, heterogeneity of molecular defects of majority of diseases lies between these two extremes.

Dysmorphic syndromes

Dysmorphology is the branch of clinical genetics in which clinicians study the patterns of structural defects. Although dysmorphic syndromes are individually rare, collectively they comprise a high proportion of the conditions that affect child health. Reaching an accurate diagnosis for children with dysmorphic features is important to them and their families. It makes available all the accumulated knowledge about the relevant condition.

Molecular techniques allow us to improve our ability to make precise syndrome diagnoses. Unfortunately, responsible genes for many dysmorphic syndromes have not been identified. In fact, several apparently new syndromes have continued to be described. Just early in this year, the authors described an apparent new syndrome in two Thai siblings with postnatal-onset growth deficiency, microcephaly, cataract, prominent supraorbital ridge, large joint contractures, severe osteoporosis, cortical dysplasia, cerebellar atrophy, and mental retardation⁽¹⁾. The description of this new syndrome opens another way of research for the benefits of affected patients and their families.

For syndromes that have long been delineated, more phenotypic features and clinical findings continue to be added. Hydrolethrus syndrome is an autosomal recessive disorder characterized by hydrocephalus, micrognathia, limb anomalies and several other abnormalities, mostly in the midline structures. The syndrome was prevalent in Finland, where all of the Finnish patients were stillborn or died during the first day of life. The authors recently reported a Thai girl with a milder form of hydrolethrus, who survived beyond the neonatal period⁽²⁾.

Diagnoses of dysmorphic syndromes whose molecular defects have not been identified still largely depend on clinical criteria. Kabuki syndrome is a good example. It was first described more than 20 years ago but its true cause remains unknown⁽³⁾.

Thanks to the HGP, scientists have recently identified primary defects for several dysmorphic syndromes. One of the methods to identify the disease gene is to study monozygotic twins who are discordant for the phenotype⁽⁴⁾. After the disease gene is found, mutation analyses and genotype-phenotype correlations can be studied. Cystinosis is an autosomal recessive lysosomal storage disorder characterized by renal Fanconi syndrome and corneal cystine crystal

deposition. There are three types of the disease classified mainly on the age of onset and severity of the disease. After the disease gene was identified⁽⁵⁾, all of the three types were found to be allelic^(6,7) with some correlations between the positions of the genetic changes and the phenotypic features⁽⁸⁻¹⁰⁾. Hermansky-Pudlak syndrome is an autosomal recessive disease with albinism and bleeding diathesis⁽¹¹⁾. Mutations in at least four genes can cause the disease^(12,13). Phenotypic features from each gene are somewhat different⁽¹⁴⁻¹⁶⁾; for example, patients with mutations in *HPS2* gene tend to have neutropenia, which does not usually occur in patients with mutations in other genes⁽¹⁷⁾.

Thai patients with many syndromes have had similar clinical and molecular features to other populations. These include multiple endocrine neoplasia type 2A⁽¹⁸⁾, achondroplasia⁽¹⁹⁾, Crouzon syndrome⁽²⁰⁾, Apert syndrome⁽²⁰⁾ and Pfeiffer syndrome⁽²¹⁾ (Fig. 1). These data can be used in several ways including prenatal diagnosis⁽²²⁾.

Some Thai patients, however, have distinct clinical features even with exactly the same mutations as other patients of different ethnic groups. The authors studied a 15-year-old Thai boy with an unspecified craniosynostosis syndrome who was found to be heterozygous for a 870G->T change in the *FGFR2* gene. This mutation has previously been reported in a Caucasian patient with severe Pfeiffer syndrome type 2 that is distinct from the craniosynostosis in the Thai patient⁽²³⁾.

Several Thai patients have been found to have unique genetic changes. These include Van der Woude syndrome, the most common autosomal dominant cleft syndrome characterized by cleft lip and palate with lip pits⁽²⁴⁾ and pseudoachondroplasia, an autosomal dominant skeletal dysplasia with precocious osteoarthritis⁽²⁵⁾. In addition, the authors found a Thai patient with nasopharyngeal carcinoma (NPC) with a mutation in *FGFR3* gene. It was the first time an *FGFR3*'s role was demonstrated in the development of human NPC⁽²⁶⁾.

Towards the completion of the HGP and the availability of single nucleotide polymorphisms in various ethnic groups, not only genetic defects of single gene disorders can be studied, but also attempts to understand further the genetic components of multifactorial disorders are more feasible and fruitful. The authors recently found that a maternal 677CT/1298AC genotype, a polymorphism in the *MTHFR* gene, is a risk factor for having children with cleft

lips with the odds ratios of 4.43 (95% confidence interval, 1.33-15.10). Approximately 12 per cent of Thai mothers whose children had cleft lips had such genotype. Therefore, folate supplement in a pregnant woman's diet may benefit 12 per cent of Thai children who are susceptible to CL/P due to the 677CT/1298AC genotype in their mothers⁽²⁷⁾.

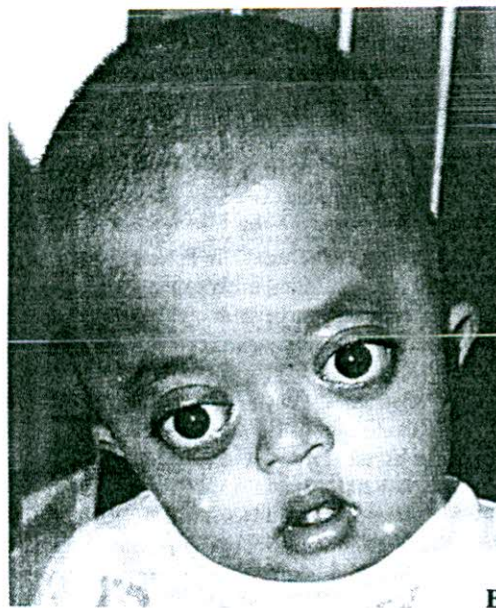
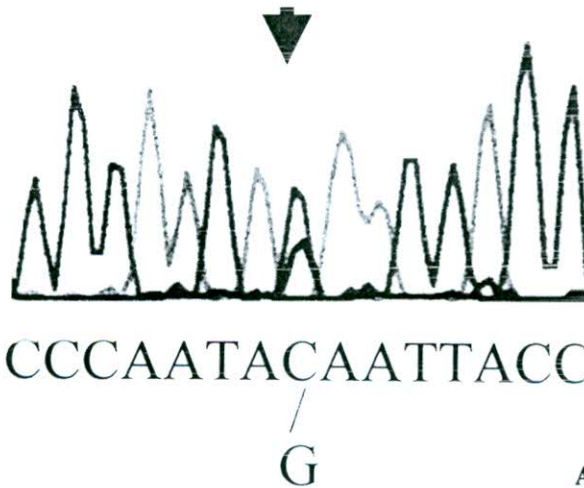


Fig. 1. The antisense sequence electropherogram (A) showing a heterozygous *FGFR2* S347C (1040C>G) mutation (arrow) helps confirming the diagnosis of Crouzon syndrome in a Thai girl with brachycephaly, exorbitism and maxillary hypoplasia (B).

Inherited metabolic disorders

Inherited metabolic disorders or inborn errors of metabolism are a group of disorders with defects in catabolic or anabolic pathways of nutrients. While they are individually rare, they collectively account for a significant proportion of illness, especially in children. They present clinically in a wide variety of ways, involving virtually any organ or tissue of the body. Accurate diagnosis is important both for treatment and prevention of disease in other family members.

Due to its unique defective point in the metabolic pathways, diagnosis of each of the diseases usually requires distinctive methods. A few disorders can be diagnosed with imaging studies; for example, Pompe disease, an autosomal recessive disorder with a defect in acid α -glucosidase leading to an accumulation of glycogen in lysosomes. Such accumulation gives a diagnostic feature under electron microscopy (28). In addition, a prenatal diagnosis for this deadly disorder can be made by this method using cells from chorionic villus sampling or amniocentesis (29).

Disorders of small molecules, such as aminoacidemia, aminoaciduria, and organic acidemia can usually be provisionally diagnosed by analyzing

plasma amino acid, urine amino acid (30) or urine organic acid profiles (31). For storage disorders and others including methemoglobinemia, essays to determine enzymatic activities are the standard diagnostic methods (32). In Thailand, however, laboratories offering such methods are scarce. On the contrary, laboratories that are able to perform molecular studies for diagnosis of these diseases are more available (33). Actually, the methods have been used to confirm diagnosis of many disorders in developed countries (34). Therefore, molecular methods should be considered as an alternative means to diagnose patients with inherited metabolic disorders in Thailand.

Molecular techniques will become more and more important diagnostic tools for assisting Thai physicians to diagnose and manage patients with dysmorphic syndromes and inherited metabolic disorders.

ACKNOWLEDGEMENT

This work was supported by the Thailand Research Fund; Contract grant number: RSA/05/2544, and The Development Grants for New Faculty/ Researchers, Chulalongkorn University.

(Received for publication on April 6, 2003)

REFERENCES

1. Shotelersuk V, Desudchit T, Suwanwela N. Post-natal growth failure, microcephaly, mental retardation, cataracts, large joint contractures, osteoporosis, cortical dysplasia, and cerebellar atrophy. *Am J Med Genet* 2003; 116: 164-9.
2. Shotelersuk V, Punyavoravud V, Phudhichareonrat S, Kukulprasong A. An Asian girl with a 'milder' form of the Hydrolethalus syndrome. *Clin Dysmorphol* 2001; 10: 51-5.
3. Shotelersuk V, Punyashthiti R, Srivuthana S, Wacharasindhu S. Kabuki syndrome: Report of six Thai children and further phenotypic and genetic delineation. *Am J Med Genet* 2002; 110: 384-90.
4. Shotelersuk V, Tiftt CJ, Vacha S, Peters KF, Biesecker LG. Discordance of oral-facial-digital syndrome type I in monozygotic twin girls. *Am J Med Genet* 1999; 86: 269-73.
5. Touchman JW, Anikster Y, Dietrich NL, et al. The genomic region encompassing the nephropathic cystinosis gene (CTNS): Complete sequencing of a 200-kb segment and discovery of a novel gene within the common cystinosis-causing deletion. *Genome Res* 2000; 10: 165-73.
6. Anikster Y, Lucero C, Touchman JW, et al. Identification and detection of the common 65-kb deletion breakpoint in the nephropathic cystinosis gene (CTNS). *Mol Genet Metab* 1999; 66: 111-6.
7. Anikster Y, Lucero C, Guo J, et al. Ocular non-nephropathic cystinosis: Clinical, biochemical, and molecular correlations. *Pediatr Res* 2000; 47: 17-23.
8. Shotelersuk V, Larson D, Anikster Y, et al. CTNS mutations in an American-based population of cystinosis patients. *Am J Hum Genet* 1998; 63: 1352-62.
9. Kleta R, Anikster Y, Lucero C, et al. CTNS mutations in African American patients with cystinosis. *Mol Genet Metab* 2001; 74: 332-7.
10. Anikster Y, Shotelersuk V, Gahl WA. CTNS mutations in patients with cystinosis. *Hum Mutat* 1999; 14: 454-8.

11. Shotelersuk V, Gahl WA. Hermansky-Pudlak syndrome: Models for intracellular vesicle formation. *Mol Genet Metab* 1998; 65: 85-96.
 12. Dell'Angelica EC, Shotelersuk V, Aguilar RC, Gahl WA, Bonifacino JS. Altered trafficking of lysosomal proteins in Hermansky-Pudlak syndrome due to mutations in the beta 3A subunit of the AP-3 adaptor. *Mol Cell* 1999; 3: 11-21.
 13. Hazelwood S, Shotelersuk V, Wildenberg SC, et al. Evidence for locus heterogeneity in Puerto Ricans with Hermansky-Pudlak syndrome. *Am J Hum Genet* 1997; 61: 1088-94.
 14. Brantly M, Avila NA, Shotelersuk V, Lucero C, Huizing M, Gahl WA. Pulmonary function and high-resolution CT findings in patients with an inherited form of pulmonary fibrosis, Hermansky-Pudlak syndrome, due to mutations in HPS-1. *Chest* 2000; 117: 129-36.
 15. Shotelersuk V, Hazelwood S, Larson D, et al. Three new mutations in a gene causing Hermansky-Pudlak syndrome: Clinical correlations. *Mol Genet Metab* 1998; 64: 99-107.
 16. Gahl WA, Brantly M, Kaiser-Kupfer MI, et al. Genetic defects and clinical characteristics of patients with a form of oculocutaneous albinism (Hermansky-Pudlak syndrome). *N Engl J Med* 1998; 338: 1258-64.
 17. Shotelersuk V, Dell'Angelica EC, Hartnell L, Bonifacino JS, Gahl WA. A new variant of Hermansky-Pudlak syndrome due to mutations in a gene responsible for vesicle formation. *Am J Med* 2000; 108: 423-7.
 18. Sunthornyothin S, Sinthuwiwat T, Shotelersuk V. A RET C634R mutation in a Thai female with multiple endocrine neoplasia type 2A. *J Med Assoc Thai*, In press.
 19. Shotelersuk V, Ittiwut C, Srivuthana S, et al. Clinical and molecular characteristics of Thai patients with achondroplasia. *Southeast Asian J Trop Med Public Health* 2001; 32: 429-33.
 20. Shotelersuk V, Mahatamarat C, Ittiwut C, et al. FGFR2 mutations among Thai children with Crouzon and Apert syndromes. *J Craniofac Surg* 2003; 14: 101-4.
 21. Shotelersuk V, Srivuthana S, Ittiwut C, Theamboonlers A, Mahatamarat C, Poovorawan Y. A case of Pfeiffer syndrome type 1 with an A344P mutation in the FGFR2 gene. *Southeast Asian J Trop Med Public Health* 2001; 32: 425-8.
 22. Phupong V, Srichomthong C, Shotelersuk V. Prenatal exclusion of Crouzon syndrome due to FGFR2 S351C mutation. Submitted.
 23. Shotelersuk V, Ittiwut C, Srivuthana S, Mahatamarat C, Lerdlum S, Wacharasindhu S. Distinct craniofacial-skeletal-dermatological dysplasia in a patient with W290C mutation in FGFR2. *Am J Med Genet* 2002; 113: 4-8.
 24. Shotelersuk V, Srichomthong C, Yoshiura K, Niikawa N. A novel mutation, 1234del(C), of the IRF6 in a Thai family with Van der Woude syndrome. *Int J Mol Med* 2003; 11: 505-7.
 25. Shotelersuk V, Punyashtithi R. A novel mutation of the COMP gene in a Thai family with pseudo-achondroplasia. *Int J Mol Med* 2002; 9: 81-4.
 26. Shotelersuk V, Ittiwut C, Shotelersuk K, Triratanachai S, Poovorawan Y, Mutirangura A. Fibroblast growth factor receptor 3 S249C mutation in virus associated squamous cell carcinomas. *Oncol Rep* 2001; 8: 1301-4.
 27. Shotelersuk V, Ittiwut C, Siriwan P, Angspatt A. Maternal 677CT/1298AC Genotype of the MTHFR Gene as a Risk Factor for Cleft Lip. *J Med Genet* 2003; 40: e64.
 28. Shotelersuk V, Shuangshoti S, Chotivitayatarakorn P, et al. Clinical, pathological, and electron microscopic findings in two Thai children with Pompe disease. *J Med Assoc Thai* 2002; 85 (Suppl 1): S271-9.
 29. Phupong V, Shuangshoti S, Maneesri S, Nuayboonma P, Shotelersuk V. Prenatal diagnosis by electron microscopy in Pompe disease. Submitted.
 30. Tangnaratchakit K, Ariyaprakai W, Tapaneya-Olam W, Shotelersuk V, Petchthong T. Cystinuria: Cause of recurrent renal stones in a 4-year-old girl. *J Med Assoc Thai* 2002; 85 (Suppl 4): S1281-6.
 31. Shotelersuk V, Srivuthana S, Wacharasindhu S, et al. Establishing gas chromatography-mass spectrometry to diagnose organic acidemias in Thailand. *Southeast Asian J Trop Med Public Health* 2000; 31: 566-70.
 32. Shotelersuk V, Tosukhowong P, Chotivitayatarakorn P, Pongpunlert W. A Thai boy with hereditary enzymopenic methemoglobinemia type II. *J Med Assoc Thai* 2000; 83: 1380-6.
 33. Champattanachai V, Cairns J, Shotelersuk V, et al. Novel mutations in a Thai patient with methylmalonic acidemia. *Mol Genet Metab*, In press.
 34. Hazelwood S, Bernardini I, Shotelersuk V, et al. Normal brain myelination in a patient homozygous for a mutation that encodes a severely truncated methionine adenosyltransferase I/III. *Am J Med Genet* 1998; 75: 395-400.
-

การวินิจฉัยกลุ่มอาการที่มีความผิดปกติทางรูปร่างและกลุ่มโรคพันธุกรรมเมแทบอลิก ด้วยวิธีทางอณูพันธุศาสตร์

วรศักดิ์ โชติเลอศักดิ์, พบ*

โรคในกลุ่มอาการที่มีความผิดปกติทางรูปร่างและกลุ่มโรคพันธุกรรมเมแทบอลิก แม้แต่ละโรคจะพบได้น้อย แต่โดยรวมแล้วนับเป็นสัดส่วนที่สำคัญของการเจ็บป่วย โดยเฉพาะอย่างยิ่งในเด็ก โรคกลุ่มนี้แสดงอาการได้ในทุกอวัยวะ ทุกรูปแบบ ทำให้การวินิจฉัยทำได้ค่อนข้างยาก อย่างไรก็ตามแพทย์จำเป็นต้องพยายามให้การวินิจฉัยที่ถูกต้อง ทั้งนี้เพื่อประโยชน์ในการรักษาผู้ป่วยและป้องกันการเกิดซ้ำของสมาชิกคนอื่นในครอบครัว

วิธีทางอณูพันธุศาสตร์ได้ปฏิวัติวิธีการวินิจฉัยโรคพันธุกรรมรวมทั้งโรคในสองกลุ่มนี้ วิธีดังกล่าวสามารถหลีกเลี่ยงจุดด้อยของวิธีการวินิจฉัยอื่น ๆ บทความนี้ได้ยกตัวอย่างโรคบางโรคในกลุ่มนี้ที่สามารถให้การวินิจฉัยได้ด้วยวิธีทางอณูพันธุศาสตร์ที่ทำได้แล้วในประเทศไทย และชี้ให้เห็นถึงประโยชน์ที่ได้ตามมาบางประการ

คำสำคัญ : การวินิจฉัยด้วยวิธีทางอณูพันธุศาสตร์, กลุ่มอาการที่มีความผิดปกติทางรูปร่าง, กลุ่มโรคพันธุกรรมเมแทบอลิก

วรศักดิ์ โชติเลอศักดิ์

จดหมายเหตุทางแพทย์ ๙ 2546; 86 (Suppl 2): S129-S134

* ภาควิชากุมารเวชศาสตร์, คณะแพทยศาสตร์ จุฬาลงกรณ์มหาวิทยาลัย, กรุงเทพฯ ๙ 10330